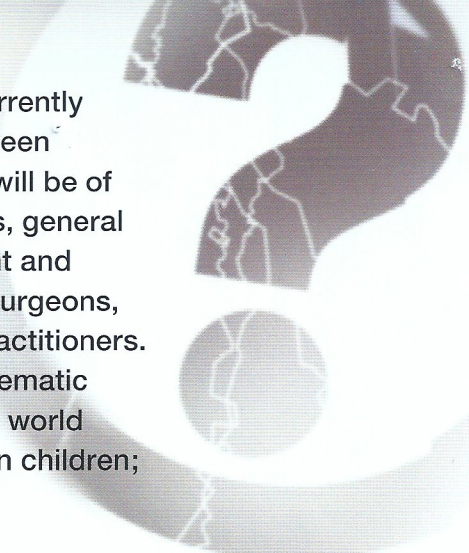




CORE-INFO:

Fractures in children



This leaflet summarises what is currently known about the relationship between fractures and physical abuse and will be of particular interest to paediatricians, general practitioners, radiologists, accident and emergency doctors, orthopaedic surgeons, social workers, police and legal practitioners. The information is based on a systematic review of all the quality work in the world literature about abusive fractures in children; full details are available at www.core-info.cardiff.ac.uk

Fractures are a normal part of growing up

- Accidental fractures are common in children: up to 66 per cent of boys and around 40 per cent of girls will sustain a fracture by their 15th birthday.
- 85 per cent of accidental fractures are seen in children over five years of age. However, they can also be indicative of abuse.
- Abusive fractures indicate a serious assault on a child.

What do we know about fractures in child abuse?

- Fractures occur in a significant proportion of physically abused children; studies record figures ranging from 11-55 per cent. 80 per cent of these fractures are in children under 18 months.
- Any bone in the body can be broken as a result of child abuse.
- Many abusive fractures are not clinically obvious unless x-rays are taken, especially in infants under two years.
- Fractures, particularly rib fractures, may not be accompanied by bruising.

How do you know if a child has a fracture?

Fractures in very young children may present with non-specific symptoms and may only be revealed by x-ray or other radiological tests. Fractures may not be obvious even on x-ray immediately after the injury; they are easier to identify once the bones show some signs of healing.

How do you find the fractures?

Abused children frequently have multiple fractures and these may be of different ages. Where physical abuse is suspected, specialised x-rays should always be taken of children under two years and may need to be taken of some older children. Two types of x-ray may be used.

Skeletal survey

This is a series of plain x-rays of all the bones in the body; detailed guidelines are available in *Standards for radiological investigations of suspected non-accidental injury* (RCPCH/RCR, 2008) www.rcpch.ac.uk/Publications. Although acute rib fractures and metaphyseal fractures are particularly difficult to see:

- oblique views of the chest increase the recognition of rib fractures
- repeat skeletal survey images 11 to 14 days later may show healing fractures not originally visible.

Radionuclide bone scan

- A radionuclide bone scan uses a radioisotope to identify a hot spot, a healing reaction, at the site of a fracture. It is a specialised x-ray which is particularly good at detecting recent fractures and may show additional fractures not evident on the skeletal survey. However, a bone scan will miss skull fractures and may miss metaphyseal fractures.

As either test may miss different fractures, consideration should be given to performing both.

Does a skeletal survey or bone scan lead to an excessive radiation dose for the child?

Any x-ray carries a radiation dose, and this must be balanced against the potential gain from performing the x-ray. A skeletal survey varies in the amount of radiation, but is roughly equivalent to the radiation from 7-20 transatlantic flights.

A bone scan is higher than this but the risk from radiation is still regarded as low.

The risk of harm from the x-ray is far outweighed by the benefit of detecting fractures in an infant less than two years of age and protecting them from further abuse.

Can you tell how old a fracture is?

Although a recent fracture can be distinguished from an old fracture, radiologists can estimate the age only in weeks, not days. Despite fractures showing predictable x-ray features over time as they heal, dating of fractures in abused children can be difficult if:

- no accurate description of the cause or timing of the injury has been given
- further injury to an already broken bone occurs
- the bone has not been immobilised, which may alter the rate of healing.

When should you be concerned that a child may have been abused?

The following apply in the absence of organic bone disease.

- Rib fractures are highly indicative of abuse in children who have not been in a major accident.
- A femoral fracture in a child who is not walking can be suggestive of abuse. A spiral fracture is the commonest fracture of the femur in abused children younger than 15 months; in all other age groups, a mid-shaft fracture is the commonest accidental or abusive femoral fracture.
- Metaphyseal fractures in very young children are more likely to be due to abuse than to accidental causes.
- A spiral or oblique fracture of the shaft of the humerus is more likely to be due to abuse than accidental causes in young children, but a supracondylar fracture is highly suggestive of accidental injury.
- In infants, it is difficult to distinguish accidental from abusive skull fractures because the commonest type of fracture from both causes is a simple linear fracture.
- Tibia and fibula fractures in children under 18 months are indicative of abuse.
- Multiple fractures are frequently seen in abused children; these may show different stages of healing.

In the literature there are examples of abusive fractures to the vertebrae, pelvis, hands and feet, scapula, clavicle and first rib. Skeletal surveys and bone scans must therefore be carefully scrutinised to exclude the possibility of such fractures.

Implications for practice

A fracture, like any other injury, should never be interpreted in isolation. It must always be assessed in the context of the child's medical and social history, developmental stage and explanation given. Any child with unexplained signs of pain or illness should be seen promptly by a doctor.

In the following situations there should be a careful evaluation to exclude child abuse:

- children under 18 months with a fracture
- children whose fracture is inconsistent with their developmental stage
- multiple fractures, particularly of different ages, in the absence of an adequate explanation
- rib fractures in children with normal bones and no history of major accidents
- a fractured femur in a child who is not yet walking.

Should all brothers and sisters of an abused child have a skeletal survey?

There is insufficient evidence in the literature to give clear guidance on this at present. The risk to each child must be assessed, and decisions regarding skeletal surveys taken accordingly.

Glossary

Metaphyseal fracture

Also known as a *bucket handle, chip or corner fracture*, this occurs at the growing end of the bone and only in children. Recent fractures are very difficult to see but become more obvious after 11 to 14 days. They are thought to happen when the baby has been pulled or swung violently and the relatively weaker growing point of the bone breaks, although there may be no outer sign of a fracture. They have been noted to occur accidentally following birth injuries, following serial casting of Talipes (club foot) or as a consequence of inappropriate physiotherapy to newborn babies.

Radionuclide bone scan

A radionuclide bone scan uses radioactive dye that the body disposes of rapidly and causes no harm. On a radionuclide bone scan a *hot spot* is an area of bone where more dye is taken up than expected. This may be due to a fracture, which would then be confirmed with a conventional x-ray.

Spiral fracture

This refers to the direction in which the bone is fractured. It implies that there has been a twisting force to cause the fracture. Spiral fractures can also occur accidentally in the femur once the child is walking.

Supracondylar fracture of humerus

This refers to a fracture of the upper arm, immediately above the elbow.